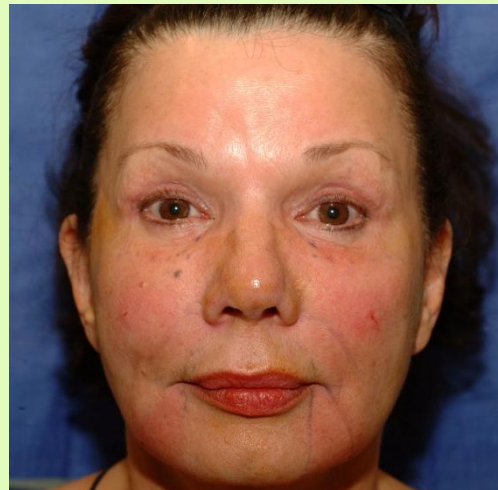


58 Y/O - FEMALE PATIENT

PROCEDURE PERFORMED BY JAIME R. GARZA, MD, DDS



Pre-Op



Immediately After Procedure



2 Days Post-Op